

STANDARD TREATMENT WORKFLOW (STW)

INTERTROCHANTERIC FEMORAL FRACTURES

S.C. Goel¹, R K Arya², Alok C Agrawal³, Vijay Jain⁴, CP Pal⁵, Vineet Sharma⁶, Sanjeev Gaur⁷, Samarth Mittal⁸, Sandeep Kumar⁹, Apoorva Kabra¹⁰

¹Banaras Hindu University, Varanasi, Uttar Pradesh; ²Atal Bihari Vajpayee Institute of Medical Sciences & Dr. Ram Manohar Lohia Hospital, New Delhi; ³All India Institute of Medical Sciences, Raipur; ⁴Atal Bihari Vajpayee Institute of Medical Sciences & Dr. Ram Manohar Lohia Hospital, New Delhi; ⁵Sarojini Naidu Medical College, Agra; ⁶King George's Medical University, Lucknow; ⁷Gandhi Medical College, Bhopal; ⁸All India Institute Of Medical Sciences Delhi; ⁹Hamdard Institute of Medical Sciences and Research, New Delhi; ¹⁰All India Institute Of Medical Sciences Delhi

CORRESPONDING AUTHOR

Dr S C Goel, Banaras Hindu University, Varanasi, Uttar Pradesh

Email: drscgoel@hotmail.com

CITATIO

Goel SC, Arya RK, Agrawal AC, Jain V, Pal CP, Sharma V, Gaur S, Mittal S, Kumar S, Kabra A. INTERTROCHANTERIC FEMORAL FRACTURES . Journal of the Epidemiology Foundation of India. 2024;2(2Suppl):S295-S296.

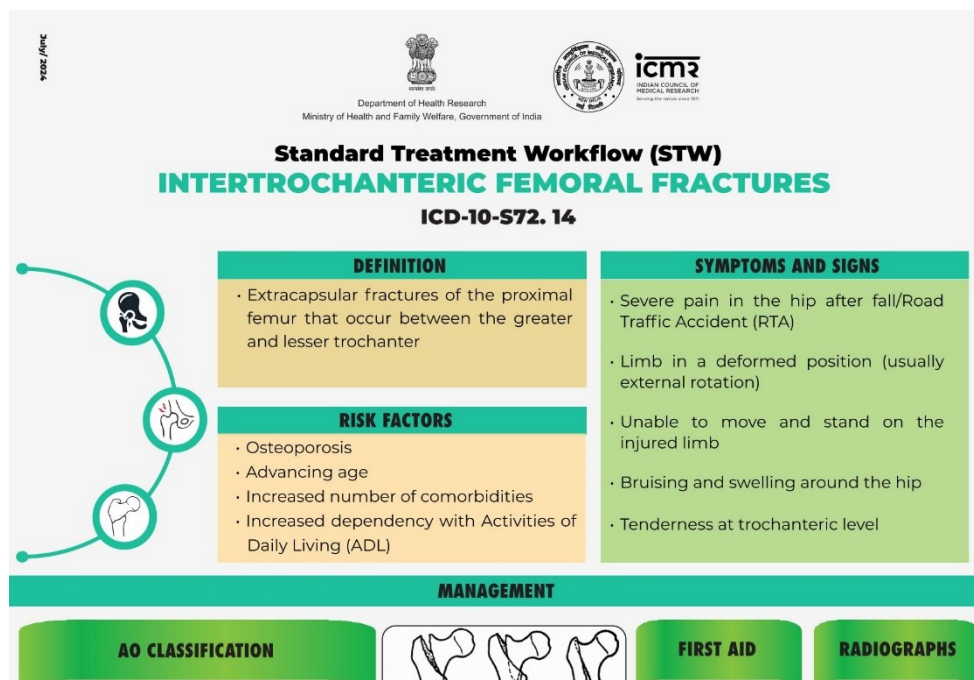
DOI: <https://doi.org/10.56450/JEFI.2024.v2i2Suppl.021>

This work is licensed under a Creative Commons Attribution 4.0 International License.

©The Author(s). 2024 Open Access

DISCLAIMER

This article/STW, was originally published by Indian Council of Medical Research (ICMR) under Standard Treatment Workflow. The reprinting of this article in Journal of the Epidemiology Foundation of India (JEFI) is done with the permission of ICMR. The content of this article is presented as it was published, with no modifications or alterations. The views and opinions expressed in the article are those of the authors and do not necessarily reflect the official policy or position of JEFI or its editorial board. This initiative of JEFI to reprint STW is to disseminate these workflows among Health Care Professionals for wider adoption and guiding path for Patient Care.





Department of Health Research
Ministry of Health and Family Welfare, Government of India

Standard Treatment Workflow (STW)
INTERTROCHANTERIC FEMORAL FRACTURES
ICD-10-S72. 14



DEFINITION

- Extracapsular fractures of the proximal femur that occur between the greater and lesser trochanter

SYMPTOMS AND SIGNS

- Severe pain in the hip after fall/Road Traffic Accident (RTA)
- Limb in a deformed position (usually external rotation)
- Unable to move and stand on the injured limb
- Bruising and swelling around the hip
- Tenderness at trochanteric level

RISK FACTORS

- Osteoporosis
- Advancing age
- Increased number of comorbidities
- Increased dependency with Activities of Daily Living (ADL)

MANAGEMENT

AO CLASSIFICATION

- AO/OTA type-31-A pertrochanteric fractures:
 - 31-A1 fractures - simple
 - 31-A2 fractures - multifragmentary -
 - A2.1: detachment of the lesser trochanter
 - A2.2: several intermediate fragments including the lesser trochanter
 - A2.3: several intermediate fragments extending more than 1 cm distal to the lesser trochanter
 - 31-A3: fractures - fracture line through the lateral femoral wall, anatomically defined as the lateral femoral cortex distal to the greater trochanter



AO CLASSIFICATION

FIRST AID

- Pain relief
- Immobilisation of limb (splintage including hip, knee and ankle to minimize movements at fracture site during transport)

RADIOGRAPHS

- X ray pelvis with bilateral hips- AP
- Involved hip with thigh – AP and lateral

OPERATIVE MANAGEMENT

- The mainstay of treatment is fixation with a dynamic hip screw (DHS) or proximal femoral Intramedullary nail
- Stable FRACTURE -intact posteromedial cortex- Association of osteosynthesis (Ao) type A1 and A2.1 -DHS
- Unstable FRACTURE - broken posteromedial cortex- Association of osteosynthesis (Ao) type A3 & A2.2 & A2.3 - Proximal femoral Intramedullary nail



31-A2



Dynamic Hip screw with plating post operative Xray

ARTHROPLASTY - INDICATIONS (RARE)

- Revision for failed internal fixation
- Associated pre-existing severe hip arthritis
- Severely osteoporotic bone that is unlikely to hold internal fixation

Red flag signs
Excessive Bruising/hematoma or any distal neurovascular deficit



31-A3



Proximal femoral nail A2 Post operative Xray

Nonoperative treatment to be considered in patients with severe comorbidities not fit for surgery understanding high risks of pneumonia, urinary tract infection, decubitus ulcers, deep vein thrombosis and mortality

ABBREVIATIONS

ADL: Activities of Daily Living

AP: Antero - posterior

DHS: Dynamic Hip Screw

RTA: Road Traffic Accident

REFERENCES

1. Hernández-Pascual C, Santos-Sánchez JÁ, García-González JM, Silva-Viamonte CF, Pablos-Hernández C, Ramos-Pascua L, Mirón-Canelo JA. Long-term outcomes of distal locking in extracapsular fractures treated with trochanteric Gamma3 nails. J Orthop Traumatol. 2021 Nov 26;22(1):48. doi: 10.1186/s10195-021-00609-4. PMID: 34825377; PMCID: PMC8620307.
2. Caiaffa V, Vicenti G, Mori C, Panella A, Conserva V, Corina G, Scialpi L, Abate A, Carozzo M, Petrelli L, Picca G, Aloisi A, Rollo G, Filippini M, Freda V, Pansini A, Puce A, Solarino G, Moretti B. Is distal locking with short intramedullary nails necessary in stable pertrochanteric fractures? A prospective, multicentre, randomised study. Injury. 2016 Oct;47 Suppl 4:S98-S106. doi: 10.1016/j.injury.2016.07.038. Epub 2016 Aug 11. PMID: 27523625.
3. Kane P, Vopat B, Paller D, Koruprolu S, Daniels AH, Born C. A biomechanical comparison of locked and unlocked long cephalomedullary nails in a stable intertrochanteric fracture model. J Orthop Trauma. 2014 Dec;28(12):715-20. doi: 10.1097/BOT.0000000000000165. PMID: 24978941; PMCID: PMC4573403.

EARLY SURGERY DECREASE COMPLICATIONS AND MORTALITY

This STW has been prepared by national experts of India with feasibility considerations for various levels of healthcare system in the country. These broad guidelines are advisory, and are based on expert opinions and available scientific evidence. There may be variations in the management of an individual patient based on his/her specific condition, as decided by the treating physician. There will be no indemnity for direct or indirect consequences. Kindly visit the website of ICMR for more information. (icmr.gov.in) for more information. ©Indian Council of Medical Research, Ministry of Health & Family Welfare, Government of India.