

STANDARD TREATMENT WORKFLOW (STW)

IMAGE GUIDED DRAINAGE OF INTRA ABDOMINAL ABSCESS

Sanjiv Sharma¹, Amar Mukund², Pushpinder Singh Khera³, Rengarajan Rajagopal⁴, Pankaj Banode⁵, N Shyam Kumar⁶, Sanjeev Kumar⁷, Manish Shaw⁸, Pradeep Hatimota⁹, Niraj Pandey¹⁰

¹All India Institute of Medical Sciences Delhi; ²Institute of Liver and Biliary Sciences, New Delhi; ³All India Institute of Medical Sciences Jodhpur; ⁴All India Institute of Medical Sciences Jodhpur; ⁵Jawaharlal Nehru Medical College Wardha, Maharashtra; ⁶Christian Medical College Vellore Tamil Nadu; ⁷All India Institute of Medical Sciences Delhi; ⁸NIMS University, Jaipur, Rajasthan; ⁹Apollo Hospital, Guwahati, Assam; ¹⁰All India Institute of Medical Sciences Delhi

CORRESPONDING AUTHOR

Sanjiv Sharma, All India Institute of Medical Sciences Delhi

Email: meetisv@yahoo.com

CITATION

Sharma S, Mukund A, Khera PS, Rajagopal R, Banode P, Kumar NS, Kumar S, Shaw M, Hatimota P, Pandey N. IMAGE GUIDED DRAINAGE OF INTRA ABDOMINAL ABSCESS. Journal of the Epidemiology Foundation of India. 2024;2(2Suppl):S263-S264.

DOI: <https://doi.org/10.56450/JEFI.2024.v2i2Suppl.006>

This work is licensed under a Creative Commons Attribution 4.0 International License.

©The Author(s). 2024 Open Access

DISCLAIMER

This article/STW, was originally published by Indian Council of Medical Research (ICMR) under Standard Treatment Workflow. The reprinting of this article in Journal of the Epidemiology Foundation of India (JEFI) is done with the permission of ICMR. The content of this article is presented as it was published, with no modifications or alterations. The views and opinions expressed in the article are those of the authors and do not necessarily reflect the official policy or position of JEFI or its editorial board. This initiative of JEFI to reprint STW is to disseminate these workflows among Health Care Professionals for wider adoption and guiding path for Patient Care.

Logo of ICMR (Indian Council of Medical Research) and Department of Health Research, Ministry of Health and Family Welfare, Government of India.

Standard Treatment Workflow STW in Interventional Radiology

IMAGE GUIDED DRAINAGE OF INTRA ABDOMINAL ABSCESS

ICD-10-KK65.1,K75.0

CLINICAL PRESENTATION

- Pain
- Fever
- Weight loss
- Anorexia
- Local tenderness
- Organomegaly

WHEN TO SUSPECT?




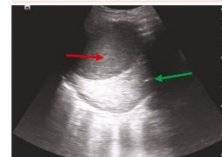

- Patient having unexplained fever especially with chills and rigors
- Local pain: Right hypochondrium (liver abscess), left hypochondrium (splenic abscess), pelvis (post operative status)
- Post operative patient developing fever and increased leucocyte count

INVESTIGATIONS

	ESSENTIAL	DESIRABLE
HEMATOLOGICAL	CBC CRP ESR	LFTs HIV serology HBs Ag
IMAGING	USG Abdomen	Contrast enhanced CT study of the abdomen

An abscess forms like a round to irregular collection within the liver parenchyma or other abdominal organs/peritoneal cavity

A: Liver abscess
B: Subdiaphragmatic abscess
C: Peri renal abscess
D: Peripancreatic abscess
E: Splenic abscess
F: Paracolic abscess
G: Right iliac fossa/periappendiceal collection



An ultrasound image showing a liver abscess (red arrow) and a normal liver (green arrow)

A coronal CT scan image showing a liver abscess (red arrow)

An axial CT scan image of the abdomen showing a liver abscess (red arrow)

An axial CT scan image of the abdomen showing a peri-renal abscess (red arrow)

Department of Health Research
Ministry of Health and Family Welfare, Government of India

icmr
INDIAN COUNCIL OF MEDICAL RESEARCH

Standard Treatment Workflow STW in Interventional Radiology

IMAGE GUIDED DRAINAGE OF INTRA ABDOMINAL ABSCESS

ICD-10-KK65.1,K75.0

CLINICAL PRESENTATION

- Pain
- Fever
- Weight loss
- Anorexia

SIGNS AND SYMPTOMS

Pain	Local tenderness
Fever	
Weight loss	Organomegaly
Anorexia	

WHEN TO SUSPECT?

- Patient having unexplained fever especially with chills and rigors
- Local pain: Right hypochondrium (liver abscess), left hypochondrium (splenic abscess), pelvis (post operative status)
- Post operative patient developing fever and increased leucocyte count

INVESTIGATIONS

	ESSENTIAL	DESIRABLE
HEMATOLOGICAL	CBC CRP ESR	LFTs HIV serology HBs Ag
IMAGING	USG Abdomen	Contrast enhanced CT study of the abdomen

An ultrasound image showing a liver abscess (red arrow) as a well-defined round area appearing less bright than the surrounding liver (green arrow)

A coronal CT scan image of the abdomen showing a large intrasplenic abscess (arrow)

An axial CT scan image of the upper abdomen showing a peripancreatic collection (arrow)

An axial CT scan image of the lower abdomen in a post cholecystectomy patient showing multiple collections (arrows)

MANAGEMENT

Treatment of an abscess depends on its:

- Location
- Size
- Degree of clinical symptoms (patient with septicemia (tachycardia, hypotension) should be treated aggressively whereas a stable patient can be discharged on oral medical treatment)

- **Medical management**
 - Send the aspirate for microbiological analysis but don't defer treatment for the result of the same
- **Drug dosages:**
 - Inj Metronidazole 500mg IV 6-8 hourly plus inj Ceftriaxone 2gm IV OD for 10-14 days (for liver and splenic abscess)
 - For pancreatic and pelvic/lower abdominal abscesses:
 - Meropenem 1-2gm IV 8 hourly plus Levofloxacin 500-750mg IV daily and Ofloxacin 200 mg for 5-7 days
 - Cefoperazone 1000-2000 mg plus Sulbactam 500-1000 mg (as a combination) IV BD for 5-7 days
- **Surgical management:**
 - To be done in cases of ruptured/impending rupture into the pericardium, peritoneal cavity and pleural cavity
- **Options include:**
 - Laparotomy
 - Chest tube placement/Video-assisted thoracoscopic surgery (VATS)

LIVER ABSCESS	RED FLAG SIGNS	SPLENIC ABSCESS	PERIPANCREATIC ABSCESS	PELVIC ABSCESS
<ul style="list-style-type: none"> • Right upper quadrant pain • May present with pleuritic right sided chest pain • Tender hepatomegaly on examination 	<ul style="list-style-type: none"> • Left lobe abscess • Segment VIII abscess: can rupture into pleura • Superficially located abscess • Abscess volume >100 ml 	<ul style="list-style-type: none"> • Left upper quadrant pain • Tender • Splenomegaly on examination 	<ul style="list-style-type: none"> • Upper abdominal pain • Patient usually has underlying acute/acute exacerbation of chronic pancreatitis <p style="background-color: #f0f0f0; padding: 2px;">RED FLAG SIGN May deteriorate rapidly if splenic vein thrombosis occurs</p>	<ul style="list-style-type: none"> • Deep seated pelvic abscess • Common in post operative patients after bowel/ gynaecological surgeries • Tender lower abdomen/ signs of peritonitis/ signs of peritonitis on examination

IMAGE GUIDED DRAINAGE

Consider image guided drainage if the patient has the following despite medical treatment:

- Persistent leucocytosis
- Signs of septicemia: tachycardia, hypotension
- Impending signs of abscess rupture on imaging

Involves Ultrasound/CT guided placement of catheter in the abscess cavity

INDICATIONS	CONTRAINDICATIONS
<ul style="list-style-type: none"> • Patient developing tachycardia and hypotension • Persistent leucocytosis • Impending signs of rupture of abscess into adjacent cavity (pleural/peritoneal/pericardial) 	<ul style="list-style-type: none"> • Uncorrectable coagulopathy • Vital structures in the approach path (large vessel, bowel)

Days of required hospitalisation: 2-5 days

Expected outcome:

- Relief in pain and tenderness within 6-8 hrs
- Resolution of fever within 24 hours

Associated adverse events that may occur:

- Vasovagal syncope (manifested as sweating, hypotension, bradycardia and loss of consciousness)

An ultrasound image showing a drainage catheter (arrow) placed within a liver abscess

How to prevent vasovagal syncope: Ensure the following

- Reassure the patient about the procedure
- Place a large bore (18G/20G) IV cannula in the arm before the procedure
- Keep normal saline infusion bag ready
- Atropine IV to be available for use

How to treat vasovagal syncope

- Raise the legs of the patient to prevent peripheral venous pooling
- Inject Atropine 0.6 mg IV if the heart rate is < 60/min (usually responds to this otherwise the same dose can be repeated after 5 min)

COMPLICATIONS	WHEN TO TAKE OUT THE CATHETER:
<ul style="list-style-type: none"> • Injury to vessels in vicinity of the abscess • Injury to the pleura in case of liver and splenic abscesses 	<ul style="list-style-type: none"> • When the output is <10 ml/24 hours

ALGORITHM FOR IMAGE GUIDED ABSCESS DRAINAGE

```

    graph TD
      A[Patient with abdominal pain, high grade fever, malaise (suspected intra abdominal abscess)] --> B[Laboratory and imaging investigations (Ultrasonography and CT) to confirm the diagnosis]
      B --> C[Start medical treatment]
      C --> D[Symptoms resolve after 3-5 days]
      D --> E{Yes}
      D --> F[No improvement/Patient develops signs such as increasing abdominal pain, tachycardia, hypotension]
      E --> G[Follow up imaging ultrasound at 1 month]
      G --> H[Continued medical Treatment]
      F --> I[Percutaneous image guided drainage of abscess]
      I --> J[Abscess volume > 100ml Superficially located liver abscess at risk of rupture into pericardium/peritoneum]
      J --> I
      I --> K[Post procedure warning signs/signifying complications]
      K --> L[Immediate step to be taken if warning signs (as shown in red flag) occur: Clamp the drainage catheter (Do not take it out), fast fluid infusion to be started]
      L --> M[Steps to be taken once complication is recognised: Appropriate imaging to look for source of bleeding (CT angiography followed by DSA if necessary), CT thorax if pleural breach is suspected]
      M --> N[POST PROCEDURE WARNING SIGNS SIGNIFYING COMPLICATIONS]
      N --> O[Frank blood in the drainage tube (haemorrhage), Drop in BP with tachycardia (haemorrhage), Patient developing breathlessness/desaturation (pneumothorax)]
      O --> P[Patient suitable for discharge: Afebrile patient with resolved leucocytosis]
      O --> Q[Follow up: Repeat ultrasound at 1 month to look for residual abscess]
      O --> R[AFTER CARE IN CASE OF UNCOMPLICATED CASES: Continue with standard medical treatment as mentioned above. Investigation: Ultrasound on day 1 and day 3 post drainage]
      
```

ABBREVIATIONS

CBC: Complete Blood Count	CT: Computed Tomography	HBs Ag: Hepatitis B surface Antigen	LFT: Liver Function Test
CRP: C-reactive protein	ESR: Erythrocyte Sedimentation Rate	HIV: Human Immunodeficiency Virus	USG: Ultrasonography

REFERENCES

- De Filippo M, Puglisi S, Di Napoli F, Girelli F, Padalino L, Cantafallo G, Mazzaroni U, Del Rio P, Ziganti P, Pagani F. CT guided percutaneous drainage of abdominal abscesses: a pictorial essay. *Radiol Med*. 2021 Dec;125(12):1981-1990. doi: 10.1007/s11547-021-0440-6. Epub 2021 Aug 26. PMID: 34569705. [PMID: 34569705]
- Robert B, Tait T, Debnobau JM. Radiologic drainage of post-operative collections and abscesses. *J Vis Surg*. 2012 Jun;2005(Suppl1):18. doi: 10.1071/surg.2012005.005. Epub 2012 Jun 20. PMID: 22879778.
- Jain N, Bhatia SC. Image guided percutaneous drainage of abscess. *Indian Radiol Phys*. 2016 Aug;50(4):529-38. doi: 10.1007/s12220-016-0549-3. PMID: 27459492.
- Zhao N, Li Q, Liu J, Yang Z, Peng T. CT guided special approaches of drainage for intraperitoneal and pelvic abscesses: One single center's experience and review of literature. *Medicine (Baltimore)*. 2018 Oct;97(24):e13066. doi: 10.1097/MD.0000000000001205. PMID: 30335302. [PMID: 30335302]
- Sharma S, Arshad MS, Gaur HS, Gupta SC, Chatterjee SA, Chatterjee MC, Kishore BC, Kishore BB, Nandakumar PT, Kishore CB, Kishorewerth SC. ACR approved evidence based evidence management of intra-abdominal abscesses: management of intra-abdominal abscesses. *J Am Coll Radiol*. 2019 Aug;18(8):779-8. doi: 10.1016/j.jacr.2019.04.025. Epub 2019 Jul 2. PMID: 30942428.

DRAIN THE ABSCESS BEFORE IT DRAINS A LIFE

This STW has been prepared by national experts of India with feasibility considerations for various levels of health-care systems in the country. These broad guidelines are advisory, and are based on expert opinions and available scientific evidence. There may be variations in the management of an individual patient based on his/her specific condition, as decided by the treating physician. There will be no indemnity for direct or indirect consequences. Kindly visit the website of ICMR for more information: icmr.gov.in for more information. ©Indian Council of Medical Research, Ministry of Health & Family Welfare, Government of India.